

XX. *On the Development and Succession of the Teeth in the Marsupialia.* By
WILLIAM HENRY FLOWER, F.R.S., F.R.C.S., &c., Conservator of the Museum of the
Royal College of Surgeons of England.

Received April 17,—Read May 9, 1867.

ALTHOUGH the dentition of adult individuals of the animals which constitute the remarkable order, or, rather, subclass Marsupialia, has been repeatedly subjected to examination, and described with exhaustive minuteness of detail, it is a singular circumstance that most of those peculiarities of the succession of their teeth which distinguish them from other mammals appear hitherto to have escaped observation.

Professor OWEN has, indeed, established the fact that those posterior teeth of each side of each jaw which have no deciduous predecessor are, as a general rule, four in number, instead of three, as in most placental mammals*, and has further contributed some important observations upon the later stages of the dentition of one family, the *Macropodidæ*†.

Beyond this, I have not been able to find any information upon the subject. Indeed it is remarked by the author just mentioned, that “an interesting field of observation still remains open in regard to the period and order of development of the deciduous and permanent teeth, in the different carnivorous, omnivorous, insectivorous, and frugivorous marsupials.”

To supply this blank is the object of the present communication. Fortunately the materials contained in the Museum of the Royal College of Surgeons, if not quite so complete as might be desired, are amply sufficient to illustrate the main aspects of the question, and to furnish a result as interesting as it was unexpected.

Family MACROPODIDÆ.

From many observations upon the early dentition of the Kangaroos (genus *Macropus*), I will only select for description certain well-marked stages, which are sufficient to illustrate the successive steps of the process.

1. The object of the first observation which needs recording was a marsupial fœtus of a *Macropus* of uncertain species, but probably belonging to one of the larger forms. Its entire length was 6·5 inches, of which the head occupied 1·4 inch, and the tail 2 inches. The surface was destitute of hair, the margins of the lips were still adherent except in front, and the eyelids were completely closed.

* “Outlines of a Classification of the Marsupialia,” Trans. Zool. Soc. vol. ii. pp. 315–333 (1839).

† See especially Cyclop. Anat. and Physiol. Art. “Teeth,” and Cat. Mus. Roy. Coll. Surgeons, Osteol. Series, vol. i. (1853).

On examining the mouth, no traces of teeth were visible through the gums. The appearances seen after dissecting the alveoli were as follows (Plate XXIX. fig. 1):—

In the upper jaw the capsule of the first incisor was very large, and contained an uncalcified pulp, showing distinctly the form of the crown of the future tooth; behind this was a small capsule containing the rudiment of the second incisor. Further back were two capsules containing distinct pulps of two teeth of the molar series, but as yet showing no trace of calcification. In the lower jaw a large procumbent incisor, $\frac{3}{10}$ of an inch long and partially calcified, occupied the anterior portion of the ramus. Above and behind this were the uncalcified pulps of two molars; as in the upper jaw, the second was considerably larger than the first. Although these pulps were very soft, they showed distinctly the form of the summit of the crown of the future tooth. No other tooth-germs could be detected.

2. A more advanced specimen of the same genus, in which the eyes were open, and the lips separated backwards to their normal extent, measured from muzzle to end of tail 11 inches, of which the head occupied 2·6 inches, and the tail 5 inches. No teeth had protruded through the gum, but the region of the upper incisors presented a bulbous prominence; the apices of the lower incisors were almost visible through the thin covering membrane, and prominences on the alveolar borders indicated the situation in which molar teeth were shortly about to break through their superficial investments.

On dissection (Plate XXIX. fig. 2), in the upper jaw, the crowns of the first two incisors were found to be advanced in calcification, the first more forward than the second. Both presented the characteristic form and also size of the extremity of these teeth in an adult animal. The pulp of the third incisor occupied a capsule placed in the premaxillary bone at some distance from the alveolar margin. It represented only the extreme summit of the tooth, and was not calcified. Behind the premaxillary suture was a minute conical calcified canine. Behind this the calcified germs of the teeth of the molar series. These were three in number, the first having the form peculiar to the premolars of the genus, compressed, and narrower in front than behind; the second (coloured red in the figure), which was the furthest advanced both in position in the alveolus and in development, had the quadrate form and characteristic anterior and posterior transverse ridges of a true molar. The third was also a true molar, but only the tips of the cusps were calcified. Immediately above the anterior part of the second was lodged a small rounded capsule (coloured blue in the figure), of a yellowish colour, perfectly distinct, though not more than $\frac{1}{10}$ inch in diameter.

In the mandible, the large procumbent incisor, corresponding in form and size to the crown of that of the adult animal, was calcified to the length of $\frac{3}{10}$ inch. The molar series consisted of three calcified crowns, corresponding in general characters to those of the maxilla, *i. e.* having the form respectively of a premolar and two true molars, but they were rather more advanced in their growth. The capsule of a fourth was also visible; and underneath the fore part of the second tooth and to the outer side of the base of the incisor, was a small capsular germ similar to that observed in the upper jaw.

3. In the next stage of dentition, the crowns of the first and second upper incisors

project considerably from the premaxillary bone. The crown of the third, though completely calcified, is still retained in its alveolus. The canine has disappeared, but its socket is visible, and as this was a macerated skull, it may have been lost accidentally. The two anterior teeth of the molar series are in place in both jaws, and the summit of the third is on a level with the alveolar border. The tip of the lower procumbent incisor was free. The germs of the reserve teeth of the molar series were not calcified.

4. In a skull, 5 inches long, belonging to a great Kangaroo (*Macropus major*), probably about half grown (Plate XXIX. fig. 3), the first and second upper incisors are in place, the third just appearing beyond the alveolar margin; all traces of the canine and its socket have disappeared. The lower incisor projects $\frac{3}{4}$ inch beyond the front of the mandible. The three anterior teeth of the molar series described above, viz. one premolar and two molars, are in place and in use in both jaws. The crown of a posterior molar is just visible in its socket. The crown of the single reserve tooth in each jaw is completely calcified, and shows the compressed character of a premolar, having two cusps behind and one in front. It is a slightly larger tooth than the premolar which is in place.

The remaining changes in the dentition of the great Kangaroo have been described so fully by Professor OWEN that it is unnecessary to follow them here in detail. They amount, however, to this—the gradual evolution of the reserve premolar tooth in each jaw, which displaces the first tooth having the character of a true molar; the concomitant shedding of the first premolar; and the subsequent shedding of the second or reserve premolar, followed ultimately by the loss of the two anterior true molars.

The foregoing observations on the earlier stages of the development of the teeth of *Macropus* are not in accordance with the description of Professor OWEN, which runs thus. "The deciduous dentition of the great Kangaroo (*Macropus major*) is $i. \frac{3-3}{1-1}$, $c. \frac{1-1}{0-0}$, $d.m. \frac{2-2}{2-2}=18$. The canines are rudimental, and are absorbed rather than shed. The deciduous incisors are shed before the young animal finally quits the pouch; when this takes place, the dentition is $i. \frac{1-1}{1-1}$, $d.m. \frac{2-2}{2-2}=12$, the upper incisors being $i. 1$, the molars $d. 3$, and $d. 4$ of the typical dentition"*.

I have not been able to find any trace of deciduous incisors in any specimen of *Macropus* examined, and I do not think that if they had advanced to the calcified stage, in which alone the term "shed" would be applicable to their disappearance, they could have escaped observation. Further, the analogy with other marsupial genera, presently to be shown, gives me greater confidence in the belief that *Macropus* is, at all events as regards the incisors, a monophyodont.

I am also not disposed to regard the first tooth of the molar series as representing one of the deciduous molars of the typical diphyodont dentition; but the proofs upon which this view rests will appear after an examination of the dental succession in other genera.

As the general characters of the teeth of the other members of the family *Macropo-*

* Cyclop. Anat. and Phys., Art. "Teeth," vol. iv. p. 933.

didæ agree in all essentials with those of the type, differing only in the form of the crowns of the molars and premolars and the longer or shorter persistence of the rudimental maxillary canine, we may conclude that their development follows the same rule, and such observations as I have been able to make fully bear out this conclusion. Differences, however, occur in the order of the evolution of the teeth among themselves. Thus in *Hypsiprymnus*, the reserve premolar is relatively later in acquiring its position in the jaw than in *Macropus*, being still in germ, at least in some species (see Plate XXIX. fig. 4), after the last permanent molar is in place and use. This probably has relation to the extraordinary size of this tooth, and the length of time consequently required for its development. Moreover this tooth, as well as the anterior true molars, are not commonly lost during the lifetime of the animal as in the great Kangaroo.

Family PHALANGISTIDÆ.

Phalangista vulpina.

1. A marsupial fœtus, nearly destitute of hair. Entire length 8 inches, of which the head occupied 1·7, and the tail 3·5. Eyelids open. Lateral margins of the lips not adherent (see Plate XXIX. fig. 5).

There were no teeth above the gums in either jaw; but the prominent apices of the first and second upper incisors, the lower incisors, and the two anterior teeth of the molar series raised the overlying mucous membrane.

On dissection, the crowns of the three upper incisors were found to be calcified, and corresponding in form and size to those of the adult animal. The conical crown of the canine was calcified, but lay deep in the alveolus. The large temporary molar (coloured red) and the first and second true molars had also solid crowns. Above the former was a slightly calcified germ of the reserve premolar (coloured blue). The capsule of the third true molar was distinct. In the lower jaw, the large procumbent incisor was half an inch in length. An extremely minute canine, with its apex calcified, lay close to the alveolar border; the molar series resembled those of the maxilla in their development, but the germ of the reserve premolar was still a soft papilla.

2. An older specimen, well covered with hair, measured from the nose to the end of the tail 13·5 inches, of which the head occupied 2·1 and the tail 6. In the upper jaw (Plate XXIX. fig. 6), the apices of the first and second incisors protruded through the gum; as did the cusps of two molar teeth (the temporary and the first permanent molar). In the mandible, the broad, flat, cutting extremity of the incisor projected about $\frac{1}{10}$ inch beyond the membrane; the rudimentary canine was also seen, and the cusps of two molars as in the maxilla.

On dissection the appearances found resembled those described in the last specimen; but all the teeth were in a more advanced condition of development. The crowns of both reserve premolars and of the third true molar were largely calcified. No trace of the fourth true molar could be detected. Between the canine and the temporary molar was a small conical germ of one of the rudimental premolars.

A comparison of the dentition of a specimen at this age with that of an adult animal, will be quite sufficient to enable us to fill in the intermediate stages. The change which takes place is only the substitution of the reserve premolar for the temporary molar, and the complete evolution of the other teeth, including often a second rudimentary premolar*.

Phascolarctos.—The skull of the youngest Koala that I have been able to examine is 3 inches in length, that of the adult being 5. In this the permanent incisors and canines are in place, though not quite so prominent as in the adult. The single permanent premolar, and the first and second true molars are also in place, and the germs of the remaining two molars are calcified. We may infer from this, that if the premolar replaces a temporary molar, which according to analogy with the allied genus *Phalangerista*, and, as will be shown, with all other marsupials the succession of whose teeth is known, is most probable, this must take place at a very early age.

Family PERAMELIDÆ.

I have not had an opportunity of observing the earlier stages of dentition in any member of this family, but when the animal is not quite full grown, the teeth are in the condition shown in Plate XXX. fig. 1. The permanent incisors, canines, and two anterior premolars are in place. Behind these in each jaw is a very minute, rather compressed tuberculated tooth, succeeded posteriorly by the true molars of the permanent series. In the alveolus above this minute tooth, which is the temporary or deciduous molar, is lodged the germ of the posterior permanent premolar, a tooth having a large compressed, pointed triangular crown, with small anterior and posterior basal tubercles, seen *in situ* in the figure of the adult dentition, Plate XXX. fig. 2, coloured blue.

In an immature specimen of *Chæropus* the dentition is exactly in the same stage as shown in the *Perameles* (Plate XXX. fig. 1), but the temporary molar is of still smaller relative dimensions.

Family DIDELPHIDÆ.

In a young Opossum of one of the larger species (probably *Didelphys virginiana*), which measured 7.5 inches long, the tail being 2.25 and the head 1.75, the extreme points of the incisors, canines, premolars, and first molars had just pierced the gum. The state of development of these teeth is shown in Plate XXX. fig. 3; the incisors, canines, and first two premolars corresponded exactly with those of the adult animal. The succeeding tooth above and below, which in the adult is a compressed triangular premolar, was here a low-crowned, broad tooth, bristling with cusps like the true molars. Beneath it, in the lower jaw only, a minute yellow capsule of a successional tooth was found.

In a half-grown Virginian Opossum the incisors, canines, and first two premolars were fully developed, but more crowded together in the jaws than in the adult (see Plate

* I have confirmed these observations by the examination of a large series of skulls of Phalangers of various ages in the Leyden Museum.

XXX. fig. 4). The broad deciduous molar teeth were still in place (coloured red). On removing part of the alveolar wall, the calcified crowns of their successors (coloured blue) were seen, the upper one less advanced than the lower, and, as in the other genera described, placed rather anteriorly to the tooth it was destined to succeed. The form of the crowns of these reserve teeth was quite different from their molariform predecessors, being in fact that of the third premolars of the adult (Plate XXX. fig. 5).

The true molars had begun to take their place in the jaw, two in the maxilla and four in the mandible on each side, having their crowns calcified. Except those mentioned above no traces of reserve or successional teeth were seen.

We thus find in this American family of Marsupials precisely the same peculiarity in the succession of the teeth as noticed in their Australian congeners. I have been careful to verify these observations upon several other members of the genus, being unable to reconcile them with the figure given by Professor OWEN of the lower jaw of a *Didelphys* with two reserve premolar teeth, below the crowns of teeth, which, though showing the triangular pointed form of the permanent premolars, are indicated as the molar teeth of the deciduous series*.

Family DASYURIDÆ.

Genus *Thylacinus*.—In a young female Thylacine, very scantily covered with hair, and the entire length of which was 13 inches, the head being 2·8 and the tail 4, the gums were entirely edentulous (see Plate XXX. fig. 6). There was no appearance even of teeth raising the mucous membrane, except a small sharp prominence rather behind the middle of each alveolar border. On raising the membrane this was seen to be caused by a small tooth which was just elevated above the level of the bone. This tooth is the deciduous or temporary molar (coloured red in the figure). In the upper jaw it had a trihedral obtusely pointed crown $\frac{1}{10}$ inch in length from before backwards, flat externally, and having an angle projecting inwards. The fang is absent, being either not developed or absorbed; the corresponding tooth of the mandible is slightly smaller and more compressed, also rootless. The crowns of these teeth, by their hardness and whiteness, contrast with those next to be described, which have all a brown colour, and are evidently the germs of the persistent teeth. Such parts as are calcified correspond precisely in size and form with those of the adult animal; they are consequently much crowded in the jaw.

In the upper jaw the four incisors have their crowns calcified; the second and fourth lie superficially, nearly concealing the first and third. The apex of the canine is calcified to the extent of ·35 inch. The apices of the crowns of the three premolars are calcified. That of the third (coloured blue) is least developed in proportion to its ultimate size; its apex is just above and rather in front of the minute deciduous molar. The crown of the first molar is in great part calcified, that of the second to a less extent. The third could not be recognized.

* Reade Lecture "On the Classification and Geographical Distribution of the Mammalia" (1859), p. 18.

In the lower jaw the first and third incisors lie superficially, the second being deeply placed between them,—a relation which may also be observed in the fangs of these teeth in the adult animal. The canine is deeply placed in the bone, its crown partially concealed from the outer side by the third incisor and first premolar. The third premolar is placed lowest in the mandible, its apex is nearly in contact with the inner side of the base of the rudimentary temporary molar. The crown of the first molar is completely calcified, that of the second and third partially so; no germ of the fourth could be traced.

The dentition above described is one of the most interesting and instructive in the whole series. It would be desirable to examine the teeth of some member of the allied genus *Dasyurus* at a corresponding age, but of this I have as yet had no opportunity.

Family PHASCOLOMYIDÆ.

I have placed this family at the end of the series, only because it is the one upon the dentition of which there is the least satisfactory information.

In a young Wombat (*Phascolomys vombatus*) 11 inches in length, the tips of the incisors, and of the premolars and first two molar teeth, were just appearing through the gums. The extent to which calcification had taken place in these teeth and the third molar is shown in Plate XXX. fig. 7. A trace of the germ of the fourth molar was discernible. There were no vestiges of successional teeth.

It is stated of this genus by Professor OWEN that “the incisors and the first molar tooth are shed when the animal is young; the latter is superseded by the premolar tooth”*. Without further evidence, the statement as to the first may well be questioned, for even in the Rodents it has never been shown that the scalpriform incisors have deciduous predecessors; while, on the other hand, the analogy with the remaining marsupial families fully bears out the second. No details as to the mode or period at which this change occurs are given. It remains, therefore, for those who have opportunities of examining young Wombats at various ages to ascertain whether the first tooth of the molar series shown in the figure has already replaced, or is about to be replaced by another. Judging from its characters, which resemble those of the so-called “pre-molar” of the adult and not one of the true molars, I have very little hesitation in pointing to the former conjecture as the one most likely to prove correct.

From the foregoing observations, embracing members of each of the six natural families of the Marsupialia, it may be safely concluded that the animals of this order present a peculiar condition of dental succession, uniform throughout the order, and distinct from that of all other mammals.

This peculiarity may be thus briefly expressed. The teeth of Marsupials do not vertically displace and succeed other teeth, with the exception of a single tooth on each side of each jaw. The tooth in which a vertical succession takes place is always the

* Odontography (1840–45), p. 394.

corresponding or homologous tooth, being the hindermost of the premolar series, which is preceded by a tooth having the characters, more or less strongly expressed, of a true molar*.

Considerable differences occur in the various genera as to the relative period of the animal's life at which the fall of the temporary molar and the evolution of its successor takes place. In some, as *Hypsiprymnus*, it is one of the latest, in others, as *Thylacinus*, and probably *Phascolomys*, one of the earlier phenomena of dental development. Further observations on this point as opportunities occur will be interesting.

As before stated, I regard the first tooth of the molar series of the young Kangaroo as one of the premolars of the permanent series, and not (like the tooth placed immediately behind it in the first stage of dentition) as a molar of the deciduous or milk-series. It is in fact the homologue of the penultimate premolar of *Phalangista*, *Perameles*, *Didelphys*, &c. The circumstance of its being shed at a comparatively early period is in relation to the general conditions which, in this genus, cause the early loss of all the teeth between the incisor and true molar series, including the canine, and even the successional premolar. In *Hypsiprymnus* a still more potent reason prevails for its early removal, in the immense size of the successional premolar, which requires so much more space than is occupied by its diminutive actual predecessor.

It has been usual to divide the class Mammalia, in regard to the mode of formation and succession of their teeth, into two groups—the *Monophyodonts*, or those that generate a single set of teeth, and the *Diphyodonts*, or those that generate two sets of teeth; but even in the most typical diphyodonts the successional process does not extend to the whole of the teeth, always stopping short of those situated most posteriorly in each series.

The Marsupials occupy an intermediate position, presenting, as it were, a rudimentary diphyodont condition, the successional process being confined to a single tooth on each side of each jaw. This position is, however, by no means without analogy among the mammals of the placental series. In the Dugong, and in the existing Elephants, the successional process is limited to the incisor teeth. It is questionable whether the first premolar of many of those animals which have four teeth of this group, as the Dog and Hog (mandible), ever has a deciduous predecessor, at all events so far advanced as to have reached the calcified stage.

The closest analogy with the marsupial mode of succession is found among the Rodents. Here the incisors appear to have no deciduous predecessors; and in the Beaver, Porcupine, and others, which have but four teeth of the molar series, *i. e.* three true molars and one premolar, the latter is, exactly as in the Marsupials, the only tooth which succeeds a deciduous tooth. The analogy, however, no longer holds in those Rodents which have more than one premolar, as the Hare and Rabbit; for in this case each of these teeth has its deciduous predecessor.

* The convenient distinction between false molars or premolars and true molars, is well marked in the form of the crown, especially in the upper jaw, in all Marsupials.

In the preceding account I have used the term "permanent" for those teeth which remain in use throughout the animal's life, or, if they fall out (as with the rudimentary canines and the premolars of the *Macropodidæ*), do not give place to successional teeth, and I have therefore assumed that the milk or temporary dentition of the typical diphyodont mammals is represented in the Marsupials only by the deciduous molars.

It may be held, on the other hand, that the large majority of the teeth of the Marsupials are the homologues of the milk- or first teeth of the diphyodonts, and that it is the permanent or second dentition which is so feebly represented by the four successional teeth. This view is supported by many general analogies in animal organization and development, such as the fact that the permanent state of organs of lower animals often represents the foetal or transitional condition of the same parts in beings of higher organization.

Looking only to the period of development of the different teeth in some of the marsupial genera, we might certainly be disposed to place the successional premolar in a series by itself, although, indeed, all its morphological characters point out its congruity with the row of teeth among which it ultimately takes its place, the reverse being the case with its predecessor.

It is, however, almost impossible, after examining the teeth of the young Thylacine (Plate XXX. fig. 6), to resist the conclusion originally suggested. The unbroken series of incisors, canines, premolars, and anterior true molars of nearly the same phase of development, with posterior molars gradually added as age advances, form a striking contrast to the temporary molars, so rudimental in size and transient in duration. I can scarcely doubt but that the true molars of this animal would be identified by every one as homologous with the true molars of the diphyodonts, which are generally regarded as belonging to the permanent series, although they never have deciduous predecessors. Now, if the homology between the true molars of the Thylacine and those of a Dog, for instance, be granted, and if the anterior teeth (incisors, canines, and premolars) of the Thylacine be of the same series as its own true molars, they must also be homologous with the corresponding permanent teeth of the Dog.

It may be objected to this argument, that the true molars of the diphyodonts, not being successional teeth, ought to be regarded as members of the first or milk-series; but, in truth, the fact that they have themselves no predecessors does not make them serially homologous with the predecessors of the other teeth, while their morphological characters, as well as their habitual persistence throughout life, range them with the second or permanent series.

We have been so long accustomed to look upon the second set of teeth as an after development or derivative from the first, that it appears almost paradoxical to suggest that the milk or deciduous teeth may rather be a set superadded to supply the temporary needs of mammals of more complex dental organization. But it should be remembered that, instead of there being any such relation between the permanent and milk-teeth as that expressed by the terms "progeny" and "parent" sometimes applied to

them*, they are both (if all recent researches into their early development can be trusted) formed side by side from independent portions of the primitive dental groove, and may rather be compared to twin brothers, one of which, destined for early functional activity, proceeds rapidly in its development, while the other makes little progress until the time approaches when it is called upon to take the place of its more precocious *locum tenens*.

Many facts appear to point to the milk-teeth as being the less constant and important of the two sets developed in diphyodont dentition. Among these the most striking is the frequent occurrence of this set in a rudimentary and functionless, or, as it were, partially developed state. The milk-premolars of some Rodents (as the Guinea-pig), shed while the animal is *in utero*, the simple structure and evanescent nature of the milk-teeth of the Bats, Insectivores, and Seals, the diminutive first incisors of the Dugongs and Elephants, all appear to be cases in point.

On the other hand, examples of the commencing or sketching out, as it were, of the successors to a well-formed, regular, and functional first set of teeth are rarely, if ever, met with. Occasional instances of the habitual early decadence, or, perhaps, absence of some of the second or so-called permanent teeth occur in certain animals; but these are rather examples of the disappearance or suppression of organs of which there is no need in the economy, and chiefly occur in isolated and highly modified members of groups in the other members of which the same phenomenon does not take place, as the *Cheiromys* among the Lemurs, *Trichecus* among the Seals, and the recent Elephants (as regards the premolars) among the Proboscideans. They form no parallel to the cases mentioned above of the rudimentary formation of an entire series of teeth of the temporary or milk-set.

To return to the Marsupials:—If this view be correct, I should be quite prepared to find, in phases of development earlier than those yet examined, some traces either of the papillary, follicular, or saccular stages of milk-predecessors to other of the teeth besides those determinate four in which, for some unexplained reason, they arrive at a more mature growth †. Such proof as this would alone decide the truth of these speculations; and I have not at present either the requisite leisure or materials for following out so delicate an investigation. I trust that the facts already elicited are sufficiently novel and important to justify my bringing them, as they now stand, before the Society.

* Cyclop. Anat. and Phys. Art. "Teeth," vol. iv. p. 901.

† It may be remarked that the milk-tooth which alone is developed in the Marsupials corresponds homologically with that which, as a general rule, is most persistent in the typical diphyodonts, including Man, viz. the posterior milk-molar, replaced by the posterior permanent premolar.

POSTSCRIPT, *October 31st*, 1867.

Since the foregoing was sent to the Society I have met with the following observation in WATERHOUSE'S 'Natural History of the Mammalia,' vol. ii., Rodentia, 1848, p. 4, footnote:—"I have sought in vain for deciduous incisors in young *Marsupialia*; if they exist they must be shed at a very early period in these animals." This important statement appears to have passed quite unnoticed by all subsequent writers.

BURMEISTER, in his "Erläuterungen zur Fauna Brasiliens" (1856), at p. 59, has given a somewhat detailed account of the supposed "milk dentition" of the South American Opossums. He describes the teeth of young animals (corresponding in age to that shown at Plate XXX. fig. 4), taking it for granted that they are changed as in ordinary mammals.

DESCRIPTION OF THE PLATES.

The figures are all of the natural size, and drawn from specimens in the Museum of the Royal College of Surgeons. The teeth which give place to vertical successors are coloured red; the replacing teeth are blue. Those teeth which neither succeed, nor are succeeded by others, are uncoloured.

PLATE XXIX.

- Figs. 1, 2 & 3. Different stages of the dentition of *Macropus*, described at pp. 632 & 633.
 Fig. 4. *Hypsiprymnus murinus*. To show all the true molars in place before the evolution of the permanent premolar.
 Figs. 5 & 6. Two stages of the dentition of *Phalangista vulpina*, described at p. 634.

PLATE XXX.

- Fig. 1. Immature dentition of *Perameles fasciata*.
 Fig. 2. Adult dentition of the same animal.
 Figs. 3 & 4. Two stages of immature dentition of *Didelphys*, described at pp. 635 & 636.
 Fig. 5. Adult dentition of *Didelphys virginiana*, for comparison with the above.
 Fig. 6. Early condition of dentition of *Thylacinus cynocephalus*. The germ of the first upper incisor is concealed by that of the second.
 Fig. 7. Dentition of young *Phascolomys vombatus*. The premolar is coloured blue, in accordance with the conjecture expressed in the description at p. 637, although no absolute proof that it replaces another tooth has been given.

Fig. 4.

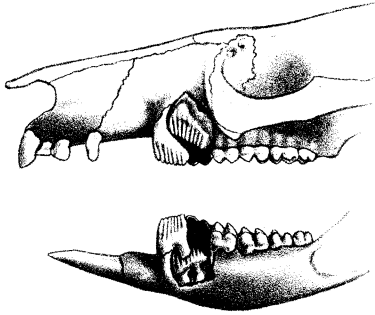


Fig. 1.

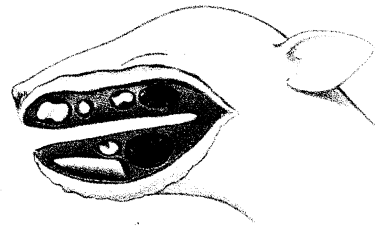


Fig. 2.

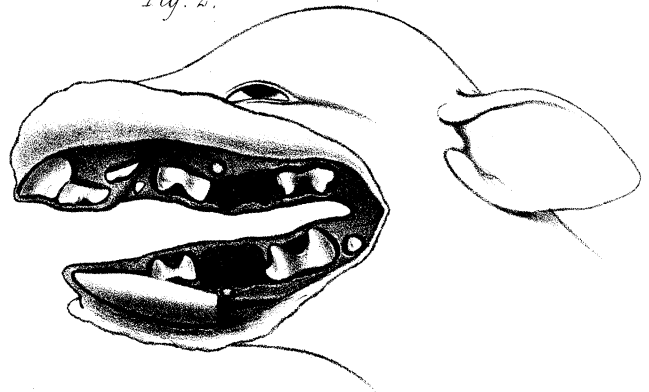


Fig. 5.

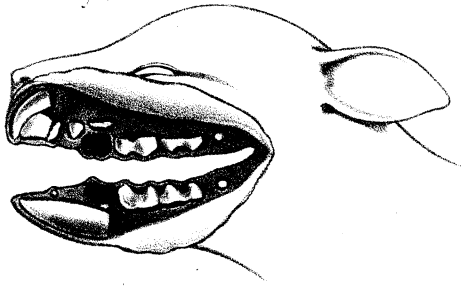


Fig. 3.

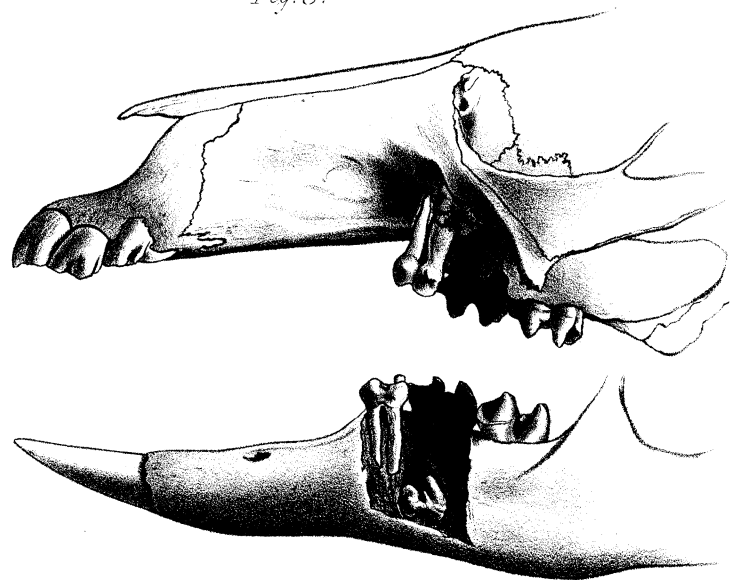
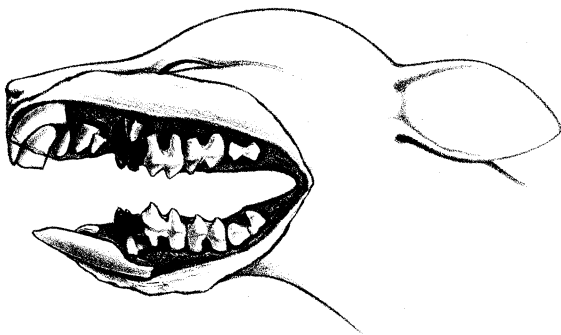


Fig. 6.



J. Smit lith.

M&N Hanhart imp

Fig 1 2 & 3. MACROPUS. Fig 4 HYPsipRYMNUMS.
Fig 5 & 6. PHALANGISTA.

Fig. 1.

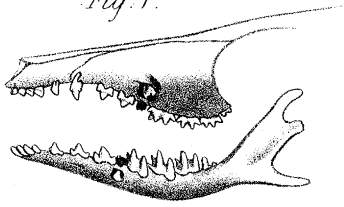


Fig. 2.

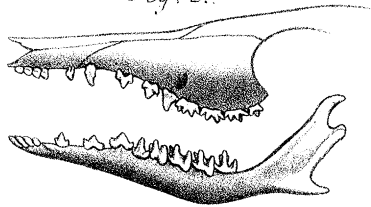


Fig. 3.

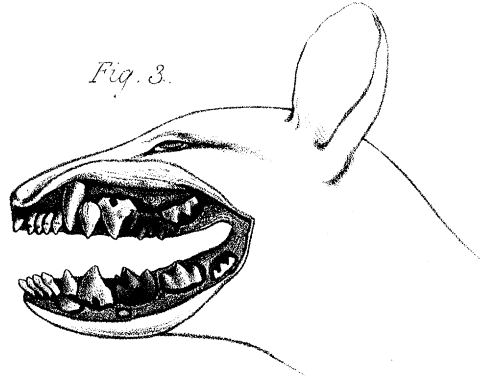


Fig. 4.

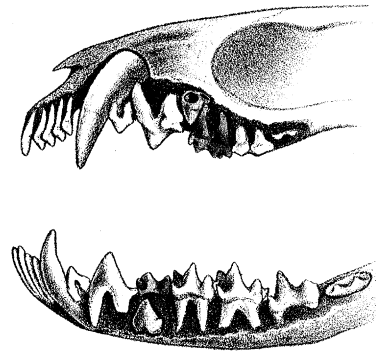


Fig. 6.

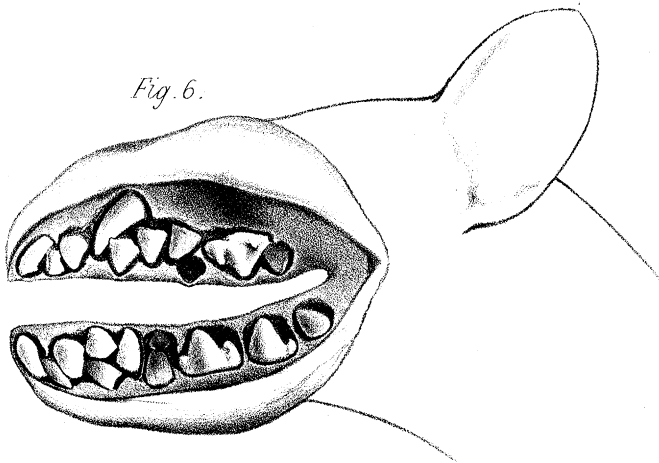


Fig. 5.

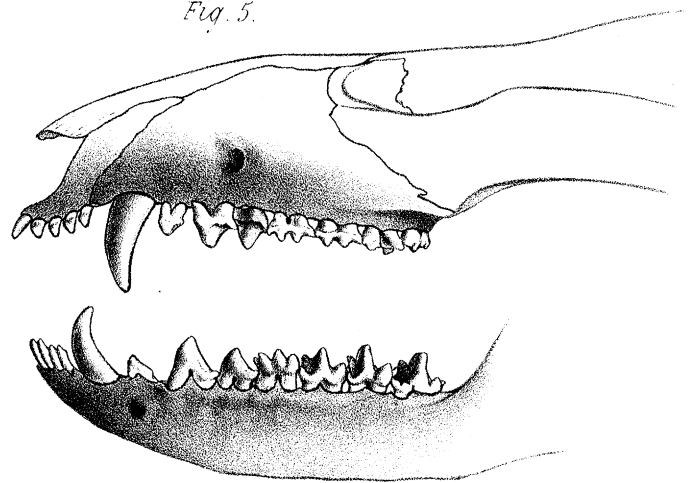


Fig. 7.

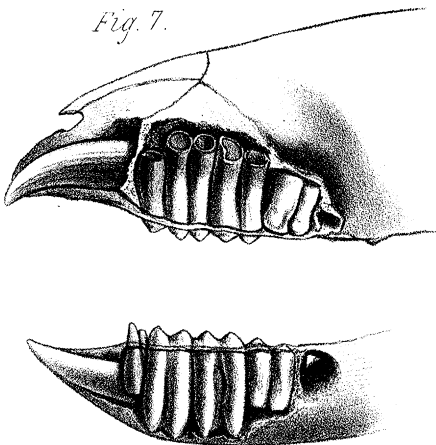


Fig 1 & 2. PERAMELES. Fig 3, 4 & 5. DIDELPHYS.
Fig..... 6. THYLACINUS. Fig..... 7. PHASCOLOMYS.

Fig. 4.

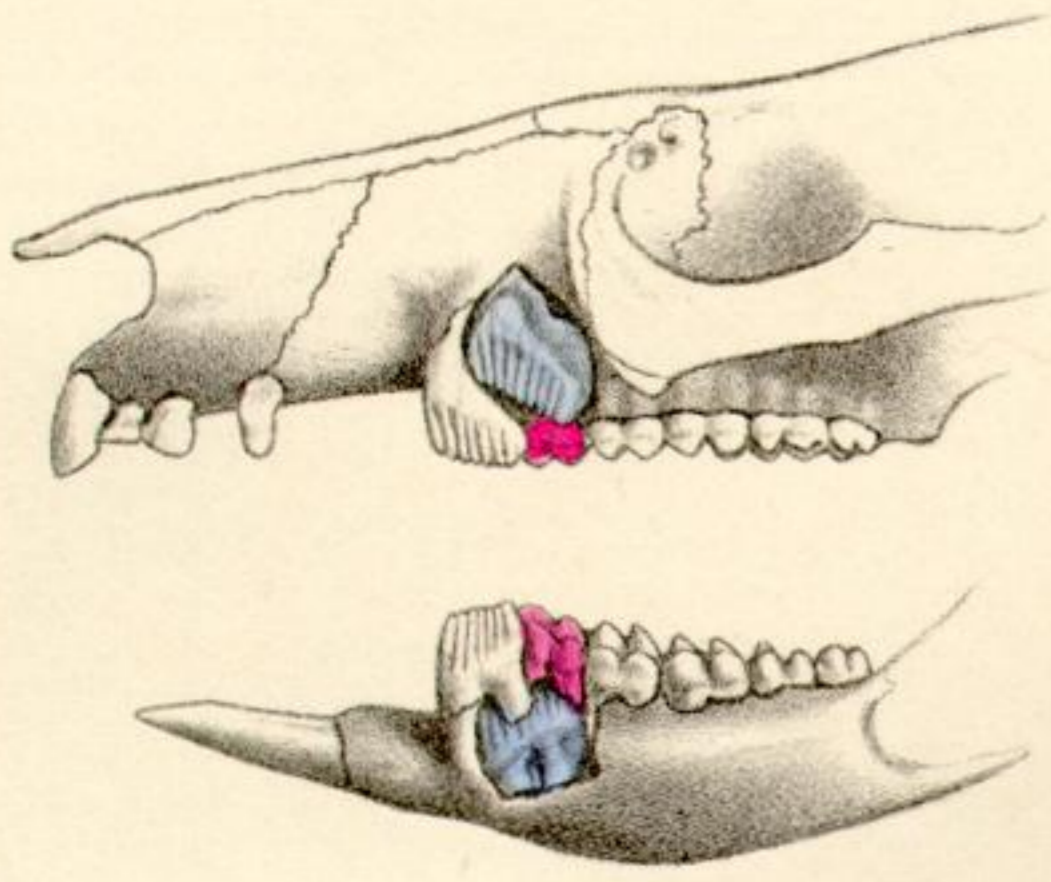


Fig. 1.

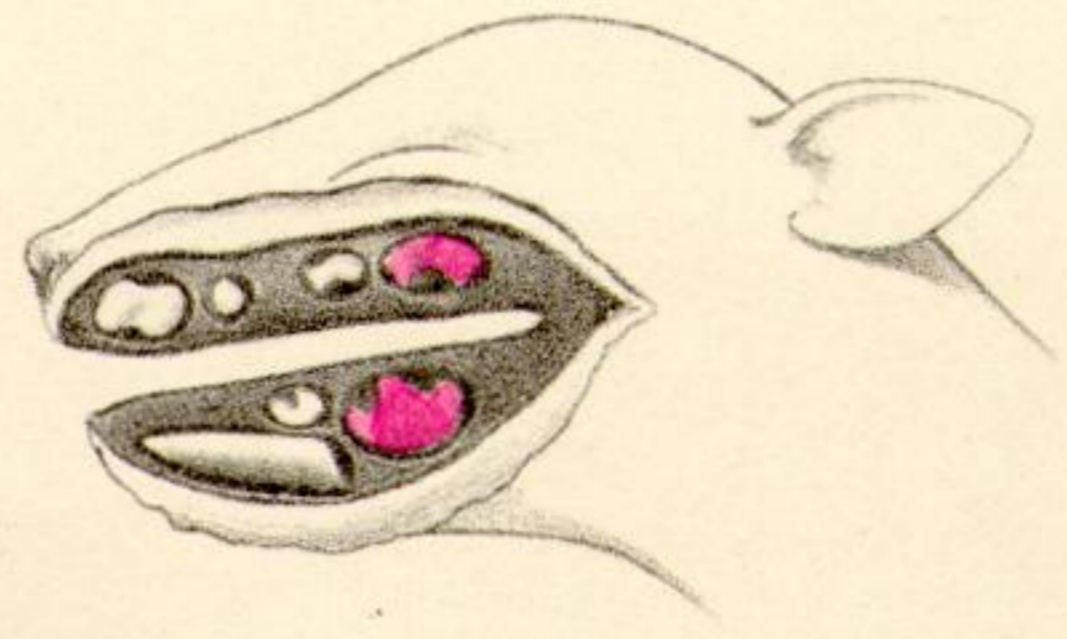


Fig. 2.

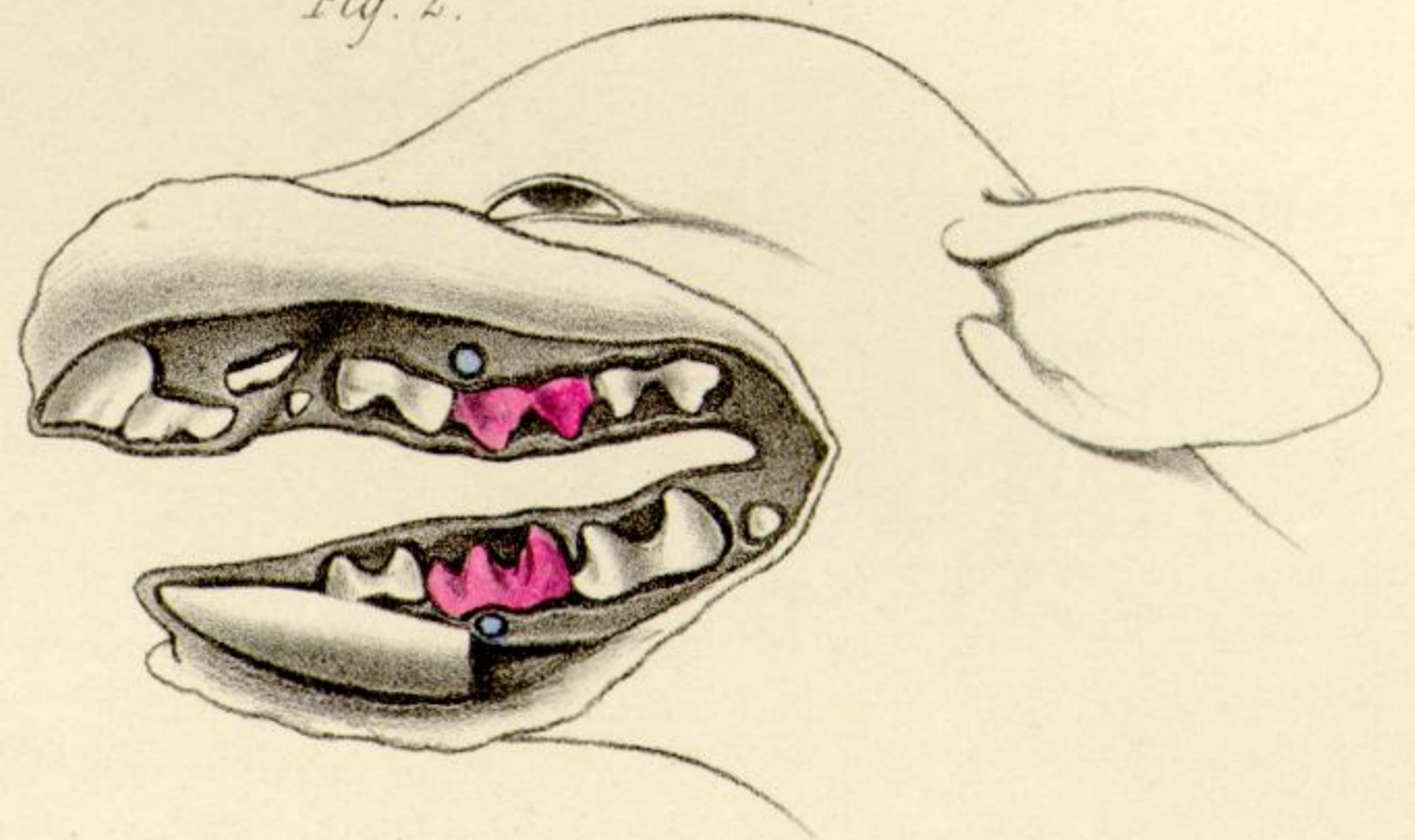


Fig. 5.

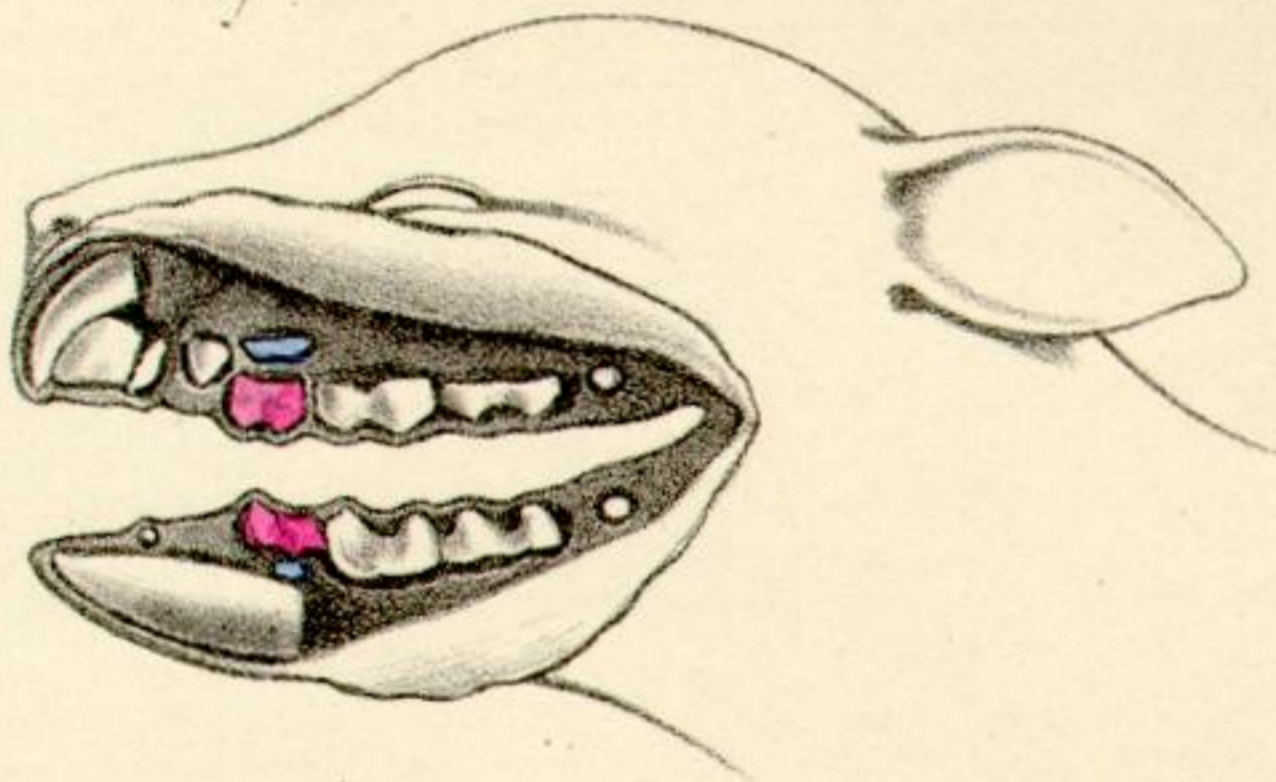


Fig. 3.

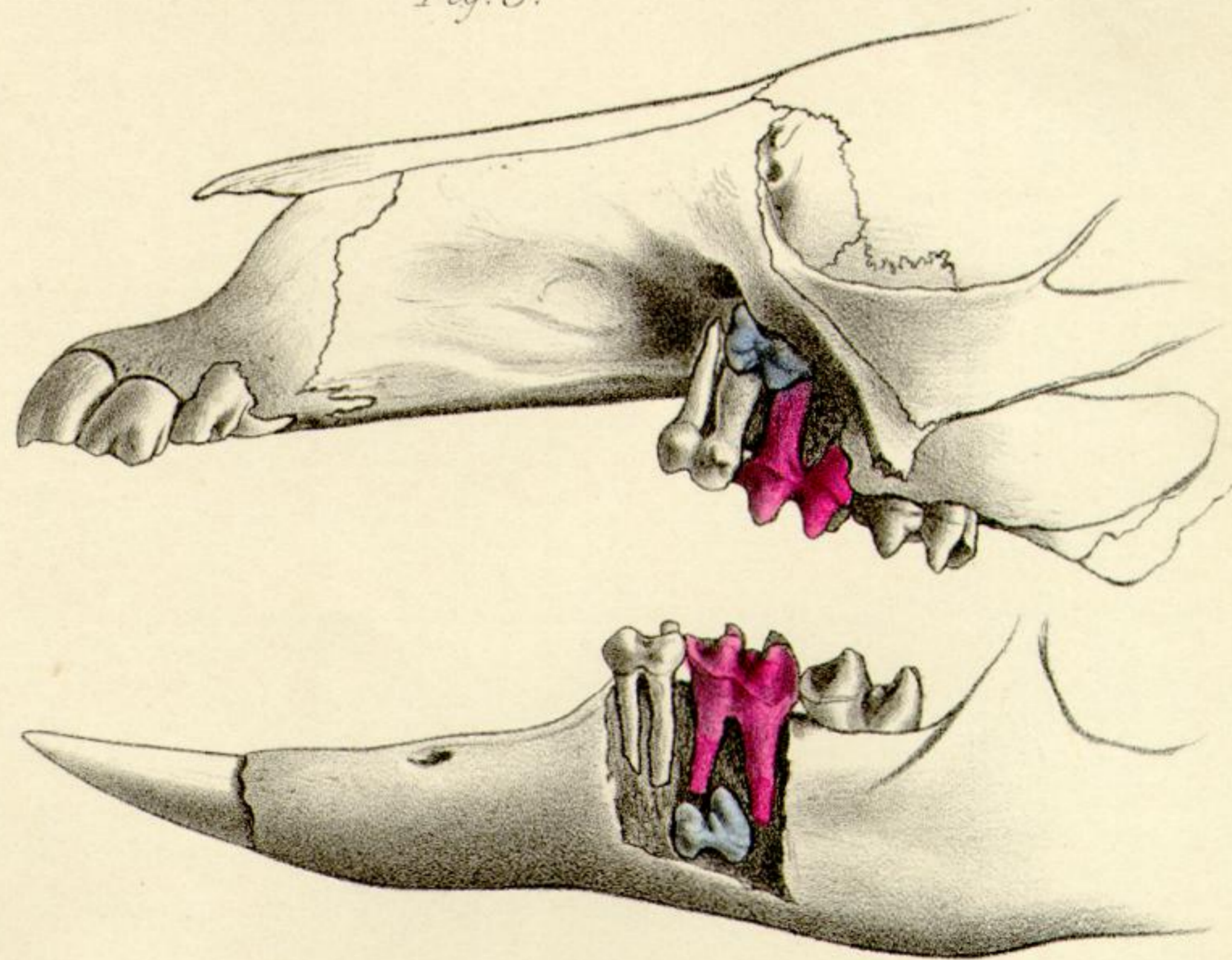


Fig. 6.

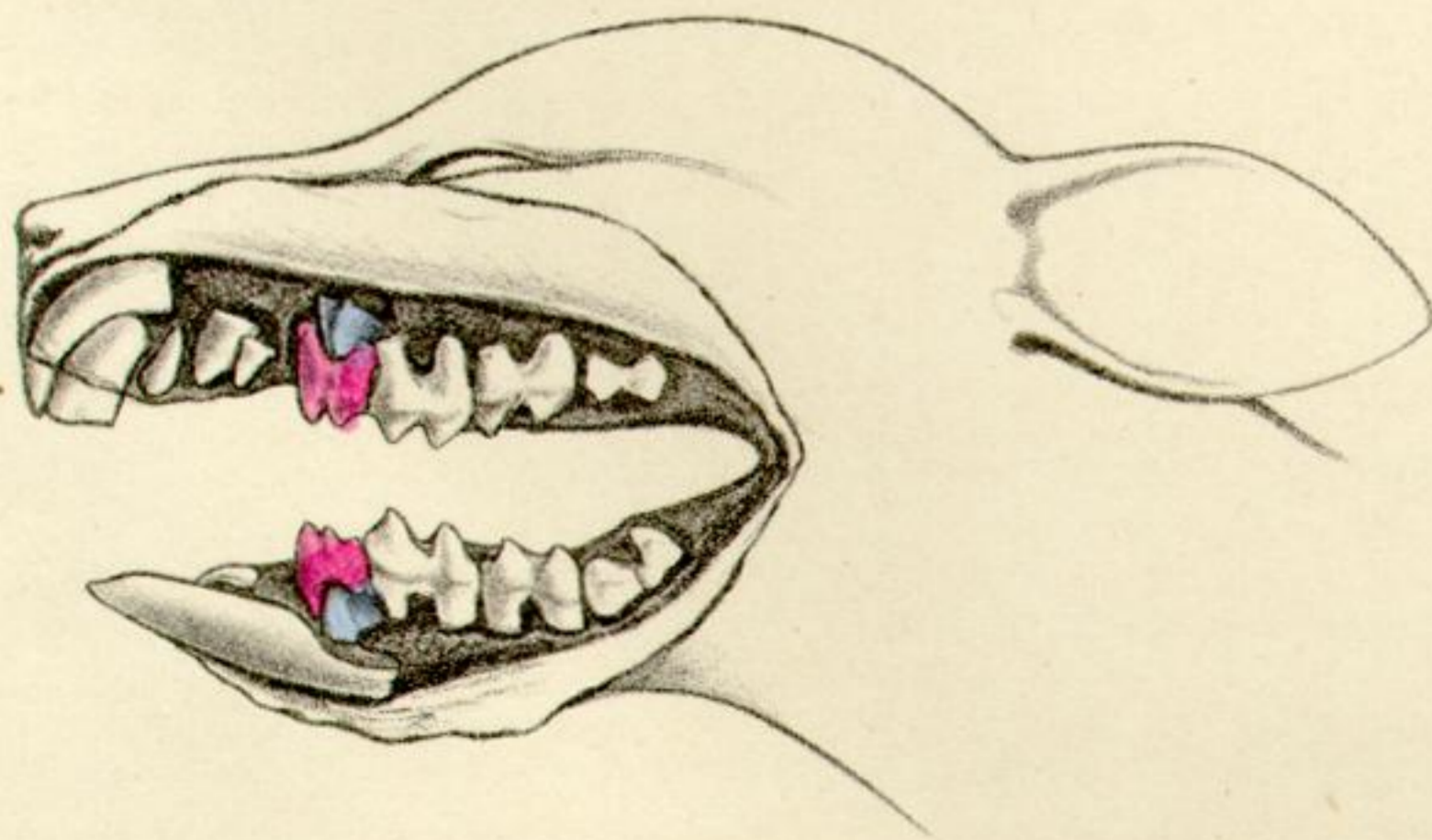


Fig 1 2 & 3. MACROPUS. Fig 4 HYPSPRYMNUMS.
 Fig 5 & 6. PHALANGISTA.

Fig. 1.

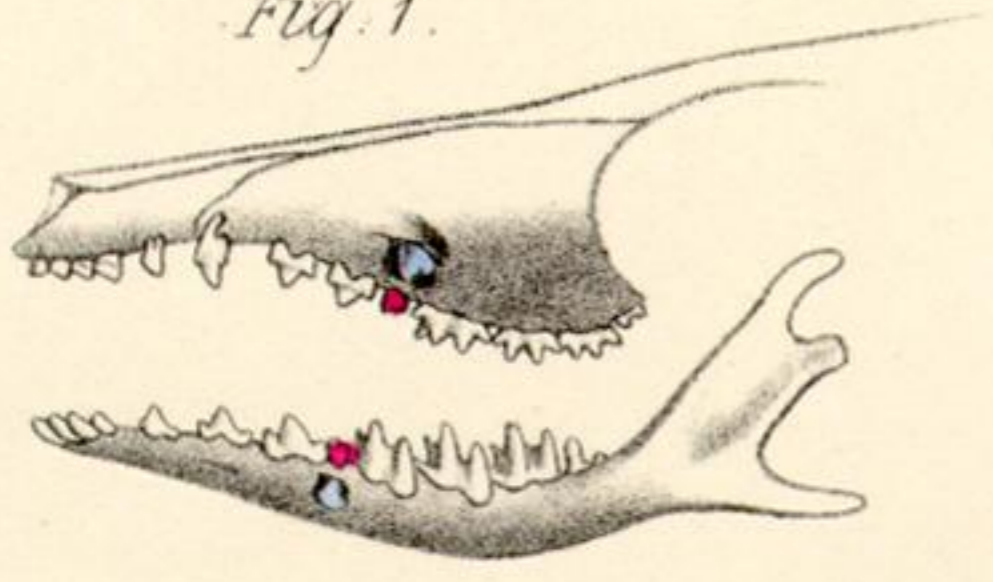


Fig. 2.

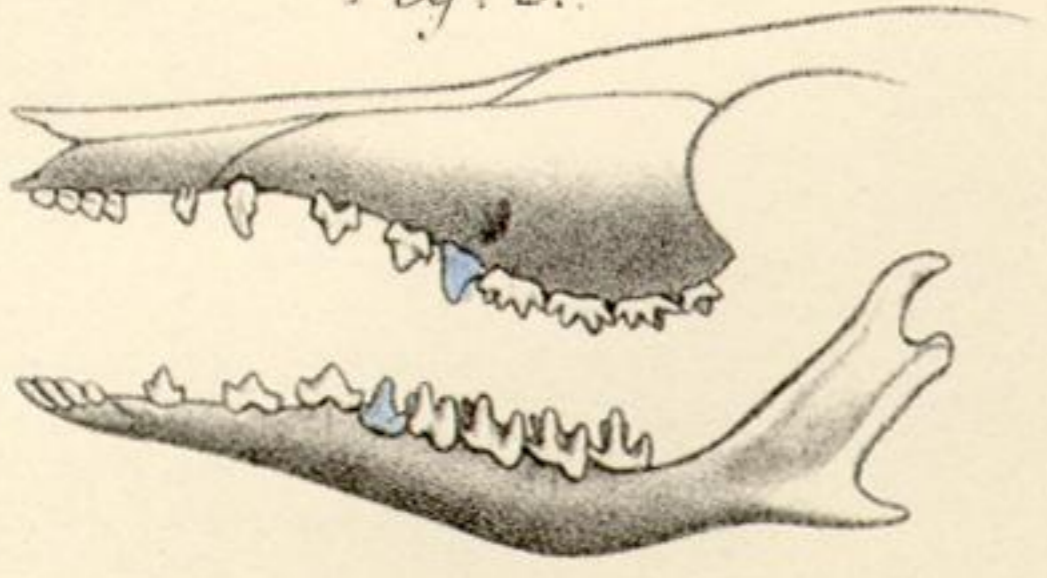


Fig. 3.

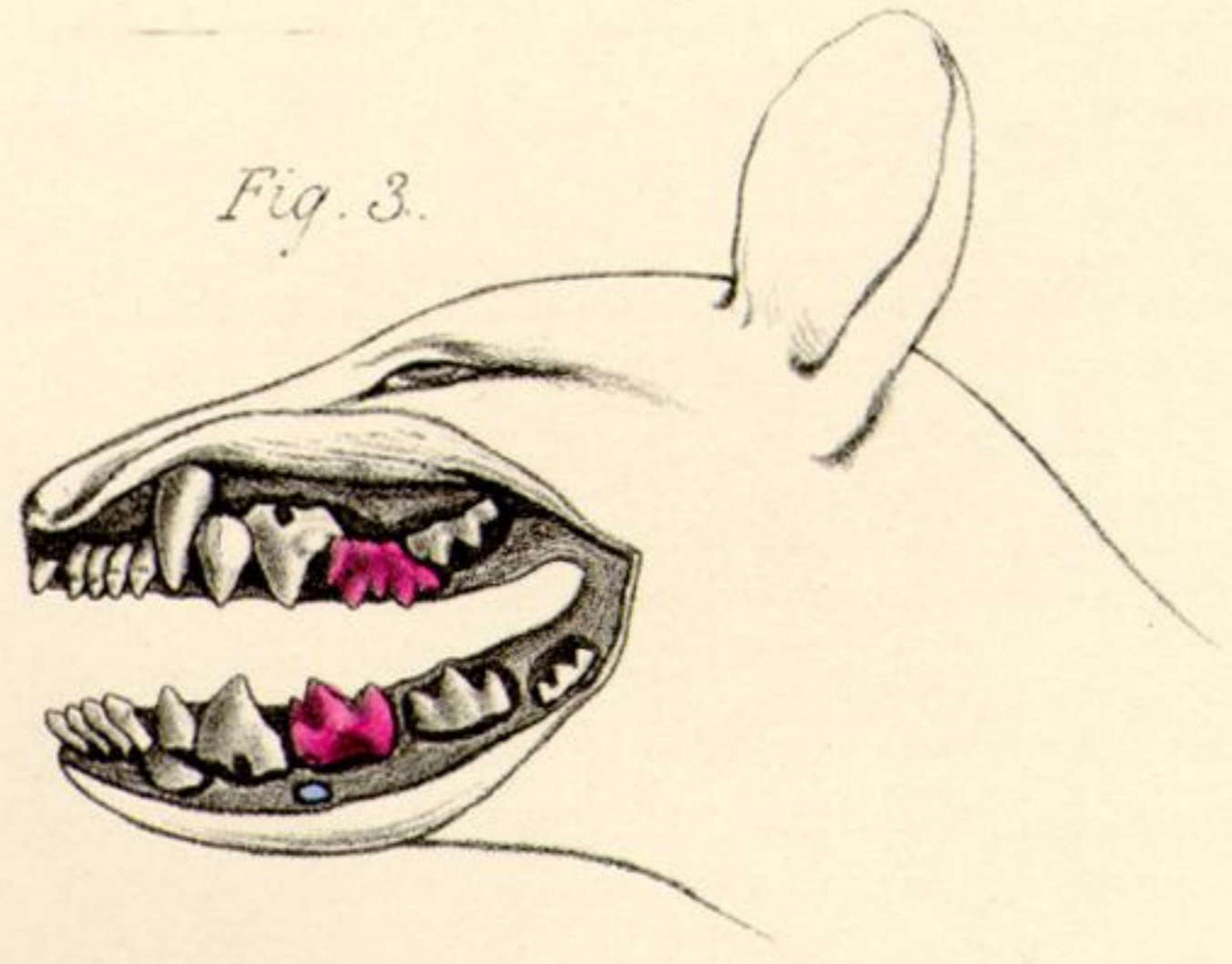


Fig. 4.

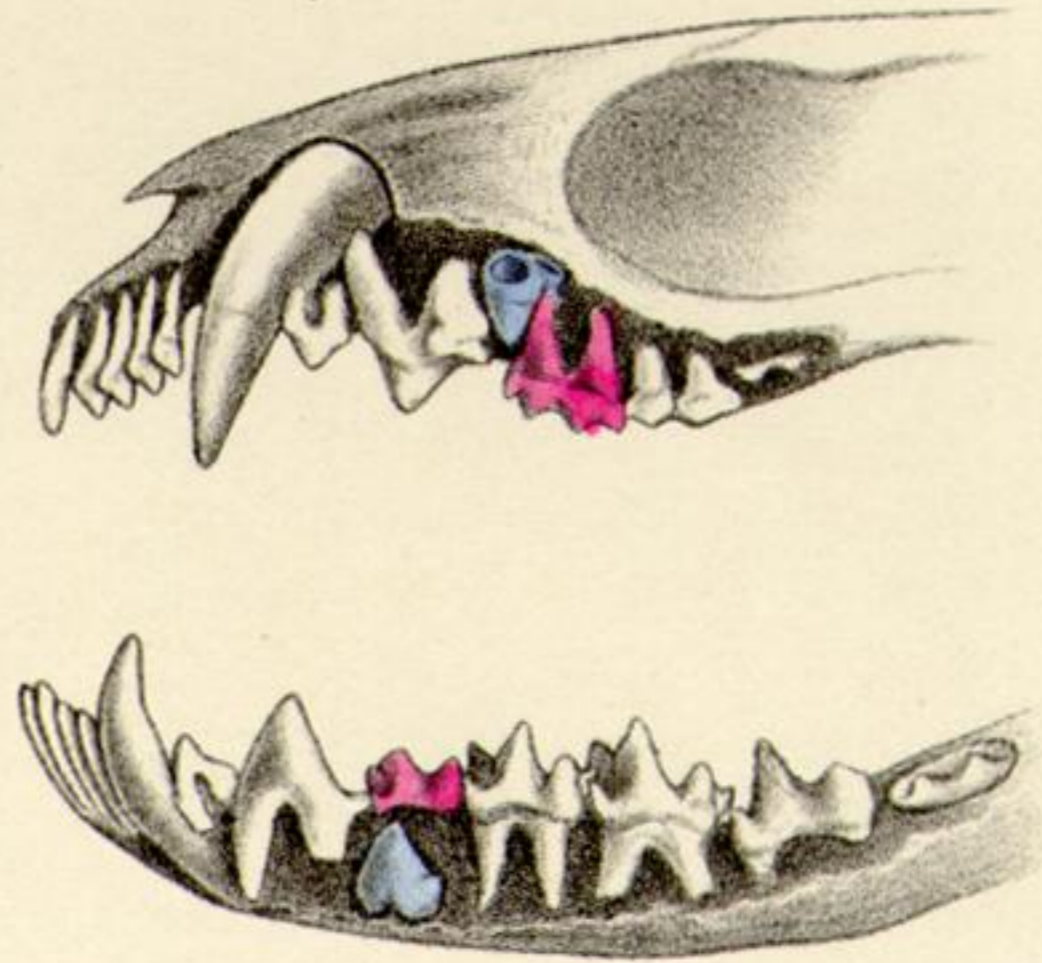


Fig. 6.

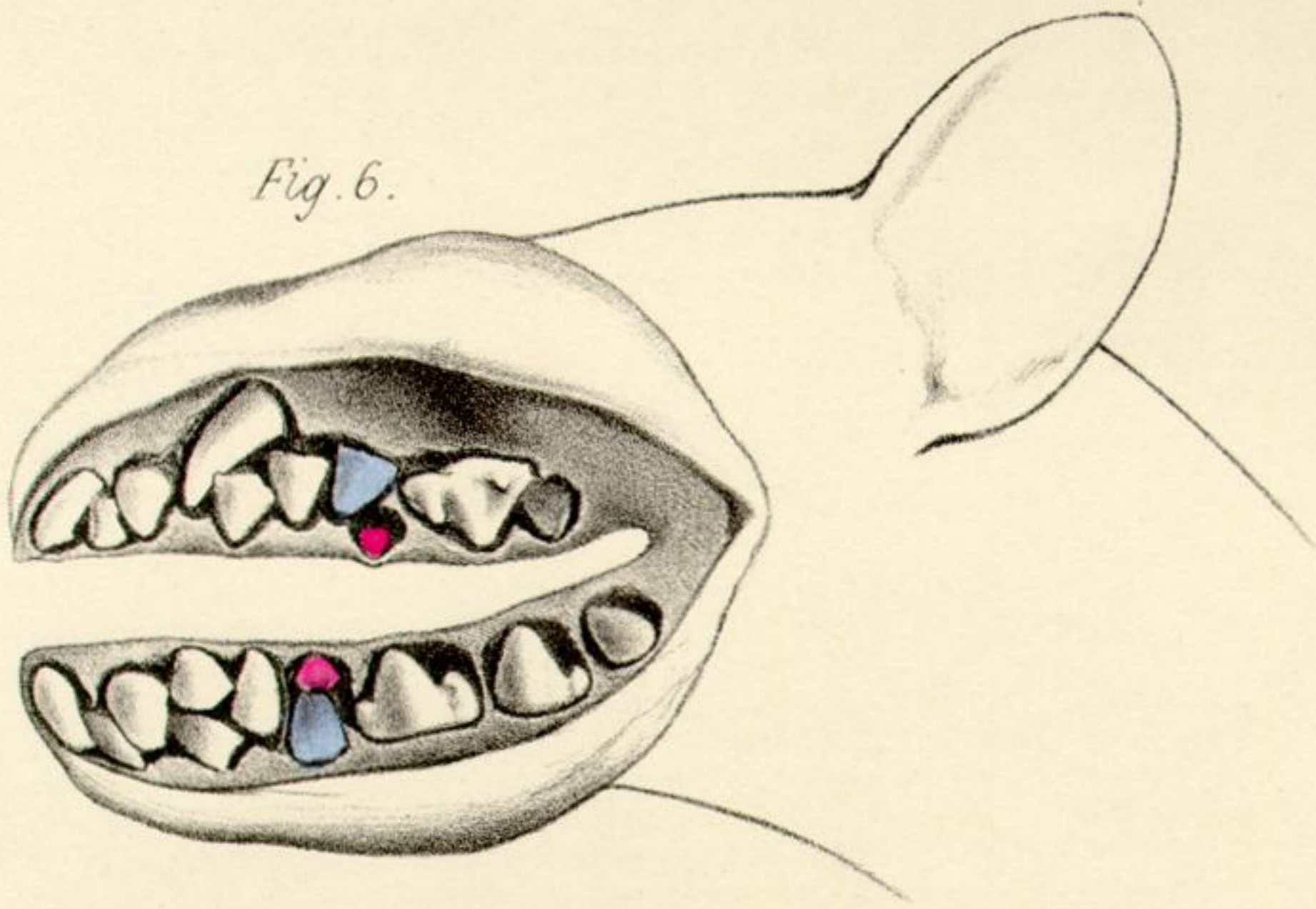


Fig. 5.

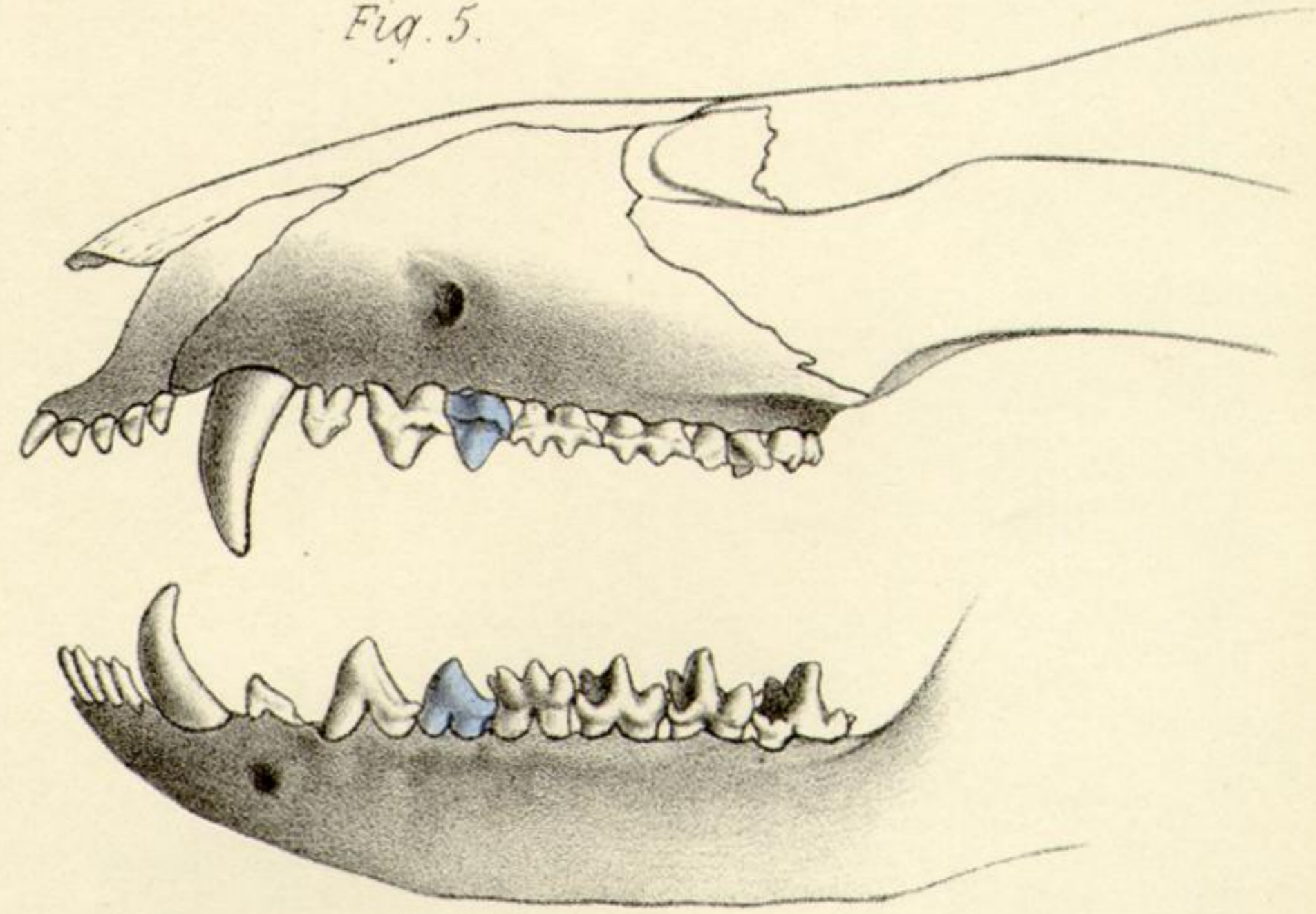


Fig. 7.

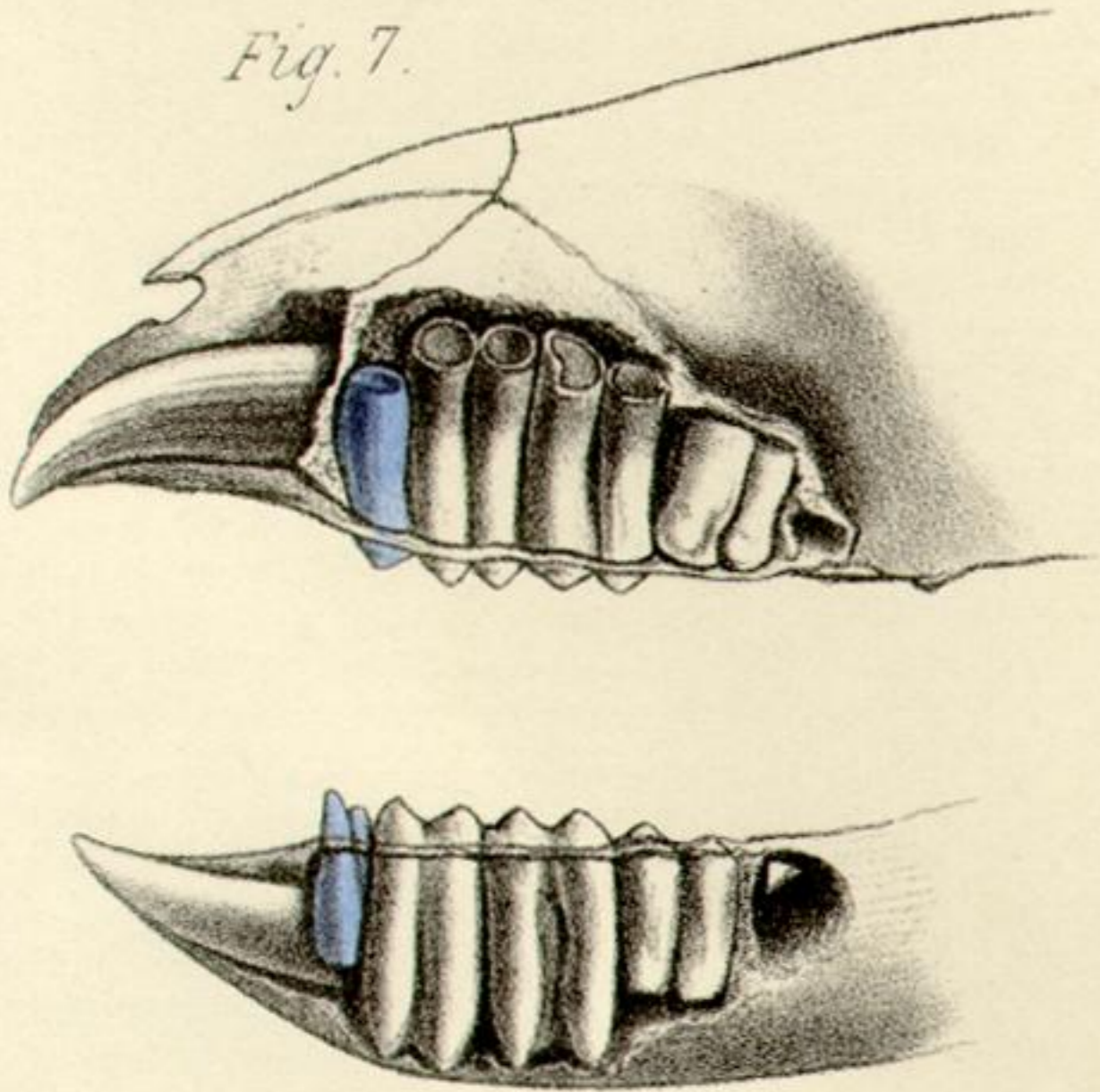


Fig 1 & 2. PERAMELES. Fig 3, 4 & 5. DIDELPHYS.
Fig..... 6. THYLACINUS. Fig..... 7. PHASCOLOMYS.